

**Short communication**

J. Perinat. Med.  
2 (1974) 69

**Combined use of amnioscopy and amniocentesis in the surveillance of twin pregnancy**

**Erich Saling**

Unit of Perinatal Medicine — Free University of Berlin  
Department of Obstetrics and Gynecology, Berlin-Neukölln

Received October 15, 1973. Accepted December 7, 1973.

Amnioscopy is the simplest and most widely used method for the estimation of slow progressive hypoxic fetal risk during the last four weeks of pregnancy [4]. A questionnaire organized together with WAGNER including 25% of all obstetrics clinics in our country showed that in 1971 85% of them used amnioscopy [5].

**In the case of a multiple pregnancy the use of this simple procedure did not appear to be fully satisfactory because there was an uncertainty about the state of the second twin.** By combining amnioscopy with amniocentesis it is now possible to supervise both twins with equal certainty. The **identification of the second amniotic cavity is made possible by the injection of a dye solution** following the aspiration of liquor at the amniocentesis. The reliability of optical examination of the liquor is very high. The antenatal mortality of the fetus supervised by amnioscopic examination is below 1 per 1,000 [4], and it must be remembered that many of those observed are "at risk". Of course, the combined method is only applicable in those cases in which the situation of the placenta or placentae permits amniocentesis.

### 1. Technical procedure

The position of the twins is first determined by ultra-sound examination which also determines a suitable point for the amniocentesis. At the same time, the thickness of the abdominal and uterine walls is measured so as to determine the depth to which the amniocentesis has to be carried. **We then perform the puncture and aspirate liquor**

**from that amniotic sac which is probably not in communication with the lower pole of the egg.** 10–20 ml of liquor are aspirated and examined by the optical method. If there is the least suspicion about it, then the liquor is centrifuged and the sediment inspected for traces of meconium. If necessary we also carry out the bubble stability test (foam test) according to CLEMENTS [1] or determinations of lecithin to judge the maturity of the fetal lung [2, 3]. The needle is not removed after the amniocentesis, but is used for the **injection of 5 ml of sterile Indigocarmin (0.02 g).** In order to get a good mixture of the dye with the liquor amnii we then encourage the patient to walk around from 5 to 10 minutes, changing her position repeatedly. After this we perform an amnioscopy. **If there is no dye visible, then it must be assumed that the injection went into the sac of the second fetus.** This surveillance is repeated at 48-hourly intervals until labor commences. Our observations would indicate that the dye disappears within two days. To be quite sure that the same gestation sac is punctured on each occasion we recommend that the amniocentesis is always carried out in the same location.

In the event that a blue discoloration is noticed during the amnioscopy performed following the amniocentesis, it must be assumed that both procedures are involving the liquor of the first amniotic cavity (Fig. 1, site of puncture X<sub>1</sub>).

In such a case it is recommended to repeat the ultra-sound examination and to reorientate oneself about the intra-uterine topography. Amnio-

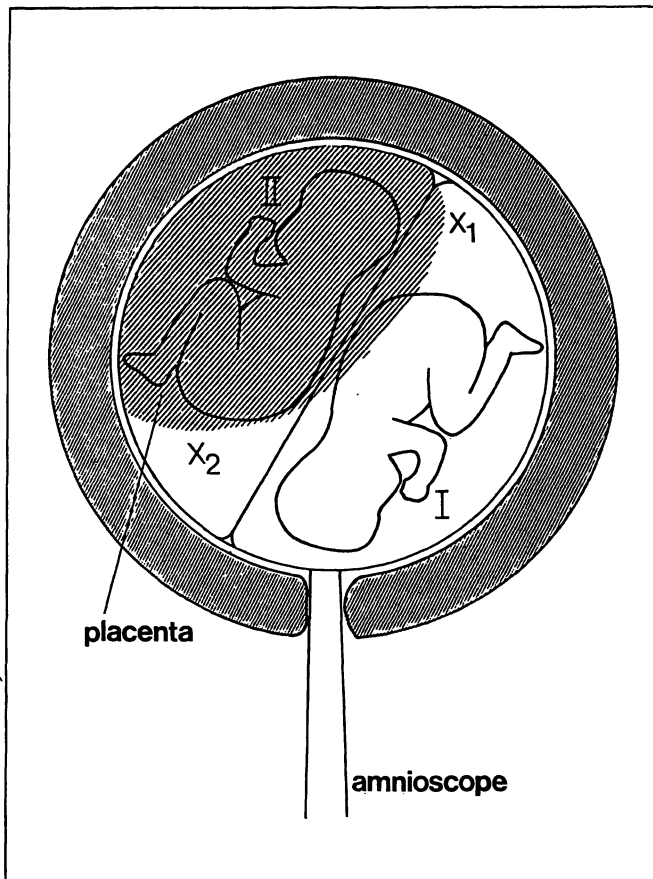


Fig. 1. Combined optical evaluation of amniotic fluid in twin pregnancy by amnioscopy and amniocentesis. The first amniocentesis attempted at point  $X_1$  was not successful. However the repetition at point  $X_2$  was successful.

centesis can then be performed at a different site, far removed from the original one but in a hopefully more suitable position with regard to the upper amniotic cavity (Fig. 1, site of puncture  $X_2$ ). If the liquor thus aspirated shows no evidence of dye, then the other amniotic sac has been found. On the other hand, if the liquor is colored, then either the desired amniotic bag has still not been identified, or else it is the relatively rare case of a common amniotic bag for both twins. It is also possible to supervise the first twin with amniocenteses instead of amnioscopies, and this would be a desirable solution for the problem of a placenta praevia or whenever it is feared that amnioscopy might induce labor.

## 2. Material

So far we have successfully used this combined procedure with four twin pregnancies. The number of patients is very small as yet but it is not expected that an increasing number will significantly change the principle of this examination. In order to show a typical situation the last case shall be briefly reported:

It was a 30-year-old para III with twin pregnancy. The first combined optical examination of the liquor (amniocentesis and amnioscopy) was done when symptoms of toxemia appeared (moderately severe edema and mild proteinuria). At that point the pregnancy was 37 weeks and 2 days advanced. The liquor in both sacs appeared to be clear at that time. 48 hours later, at a second examination, we found small amounts of meconium in the liquor obtained by amniocentesis, while amnioscopy was reported without pathological finding. Both children were thought to weigh more than 3,000 g on the basis of a combined cephalometric and thoracometric examination. The bubble stability (foam test) after CLEMENTS and co-workers [1] showed a positive result in all five tubes. It could thus be assumed that the lungs of the second twin were mature. Because of the presence of some meconium in the second bag labor was induced by rupturing the membranes. The first twin (3,260 g, 49 cm) was born spontaneously from vertex presentation. The second was extracted from foot presentation to which it was converted from a transverse lie (3,260 g, 50 cm).

Both children were in good condition, both by clinical assessment and by determination of their blood acidity (first twin: score 11/4, pH of umbilical artery 7.34; second twin: score 8/4, pH of umbilical artery 7.25).

## 3. Predictable difficulties

It is likely that with this combined method further experience is necessary before one can estimate its technical practicability and reliability. Difficulties must be expected when, for instance, the situation is unfavourable for amniocentesis because of the placental location on the anterior uterine wall or when the amniotic cavity one tries to reach is located dorso-cranially in the uterine fundus. The method described is probably also useful when more than two fetuses are contained in the uterus. However, the more amniotic sacs are present, the more difficult will be their identification.

### Summary

Amnioscopy is the simplest and most widely used method to detect slow progressive hypoxic danger to the fetus during the last four weeks of pregnancy. The procedure is not fully satisfactory in the case of a multiple pregnancy because it gives no information regarding the second twin. This disadvantage can be overcome by combining the procedure with amniocentesis, injecting dye solution into the second sac so that the condition of both fetuses can now be observed with equal assurance.

Technically the procedure is simple. After determining the lie of the twins by ultra-sound, an amniocentesis is carried out in the assumed gestation sac of the second twin.

**Keywords:** Amnioscopy, amniocentesis, perinatal supervision, twins supervision.

### Zusammenfassung

#### Kombinierter Einsatz der Amnioskopie und der Amniozentese bei der Überwachung der Zwillingschwangerschaft

Die Amnioskopie ist die einfachste und am weitesten verbreitete Methode, eine chronisch hypoxische Gefährdung des Feten (respiratorische Plazentainsuffizienz) in den letzten vier Schwangerschaftswochen zu erkennen. Beim Vorliegen einer Zwillingschwangerschaft erschien der Einsatz der Amnioskopie, nicht voll befriedigend, da Unsicherheit über den Zustand des zweiten Zwillings bestand. Durch kombinierten Einsatz der Amnioskopie mit der Amniozentese, wobei in die punktierte Amnionhöhle Farbstoff injiziert wird, besteht von nun ab die Möglichkeit beide Zwillinge mit der gleichen Sicherheit zu überwachen. Das technische Vorgehen ist einfach. Nach ultra-sonographischer Ermittlung der Lage beider Zwillinge wird an

Liquor is aspirated and examined, and at the same time Indigocarmine is injected. After 5—10 minutes an amnioscopy is carried out and the liquor of the first twin is inspected. If there is no discoloration, then the dye entered the second amniotic cavity, as intended. However, should the liquor of the first twin be discolored, then the amniocentesis must be repeated at one or more sites (Fig. 1 X<sub>1</sub>, X<sub>2</sub>). The possibility of the rare situation in which there is only one amniotic cavity for the two twins must be borne in mind. A case of the first four twin pregnancies thus supervised is reported as an example.

einer geeigneten Stelle (vermutete Amnionhöhle des II. Zwillings) die Amniozentese ausgeführt, Fruchtwasser für etwaige Untersuchungen aspiriert und anschließend Farbstoff (Indigocarmin) injiziert. Nach 5—10 Minuten folgt die Amnioskopie (Besichtigung der Amnionhöhle des I. Zwillings). Ist das Fruchtwasser am unteren Eipol nicht blau verfärbt, ist nachgewiesen, daß vorher die andere Amnionhöhle punktiert wurde. Ist das amnioskopisch betrachtete Fruchtwasser dagegen blau verfärbt (Situation in Fig. 1 bei X<sub>1</sub>) muß die Amniozentese an einer oder bei immer noch fehlendem Erfolg an mehreren geeigneten erscheinenden Stellen wiederholt werden (Beispiel Fig. 1 X<sub>2</sub>). Es kann noch der relativ seltene Fall vorliegen daß nur eine Amnionhöhle für beide Zwillinge vorhanden ist. Ein Fall aus den ersten vier auf diese Weise überwachten Zwillingschwangerschaften wird als Beispiel dargestellt.

**Schlüsselwörter:** Amnioskopie, Amniozentese, Überwachung, Zwillinge.

### Résumé

#### Intervention combinée de l'amnioscopie et de l'amnio-centèse dans la surveillance de la grossesse gémellaire

L'amnioscopie est la méthode la plus simple et de loin la plus répandue pour déceler un risque d'hypoxie chronique du fœtus (insuffisance respiratoire du placenta) dans les quatre dernières semaines de grossesse. En présence d'une grossesse gémellaire, l'intervention de l'amnioscopie s'est révélée insuffisante, car elle ne donne pas de certitude sur l'état du deuxième jumeau. Mais si on pratique une amnioscopie et une amnio-centèse en injectant un colorant dans la cavité amniotique ponctionnée, il devient possible de surveiller les deux jumeaux avec la même précision. Le procédé technique est simple. Après indication ultrasonographique de la position des deux jumeaux, on pratique l'amnio-centèse à un endroit approprié (cavité amniotique présumée du III<sup>ème</sup> jumeau), aspire le liquide

amniotique pour les examens éventuels et injecte enfin le colorant (carmin indigo). Au bout de 5—10 minutes, on effectue l'amnioscopie (exploration de la cavité amniotique du I<sup>er</sup> jumeau). Si le liquide amniotique n'est pas coloré de bleu à l'extrémité inférieure de l'oeuf («Eipol»), on a la preuve que c'est bien l'autre cavité qui avait été ponctionnée. Par contre, si le liquide amniotique observé par amnioscopie se colore en bleu (situation Fig. 1 chez X<sub>1</sub>), l'amnio-centèse doit être répétée en un endroit et même, si on échoue encore, en plusieurs endroits apparemment appropriés (exemple Fig. 1 X<sub>2</sub>). On peut se trouver aussi en face d'un cas relativement rare où il existe une seule cavité amniotique pour les deux jumeaux. Nous exposons à titre d'exemple l'un des quatre premiers cas de grossesse gémellaire observés selon cette méthode.

**Mots-clés:** Amnioscopie, amnio-centèse, surveillance, jumeau.

**Bibliography**

- [1] CLEMENTS, J. A., A. C. G. PLATZKER, D. F. TIERNEY, C. J. HOBEL, R. K. CREASY, A. J. MARGOLIS, D. W. THIBEAULT, W. H. TOOLEY, W. OH: Assessment of the risk of the respiratory-distress syndrome by a rapid test for surfactant in amniotic fluid. *New Engl. J. Med.* 286 (1972) 1077
- [2] GLUCK, L., M. V. KULOVICH, R. C. BORER, P. H. BRENNER, G. H. ANDERSON, W. N. SPELLACY: Diagnosis of respiratory distress syndrome by amniocentesis. *Amer. J. Obstet. Gynec.* 109 (1971) 440
- [3] KYNAST, G., E. SALING: Rapid specific determination of amniotic fluid lecithins as a test of fetal lung maturity. *J. Perinat. Med.* 1 (1973) 213
- [4] SALING, E.: Amnioscopy. *Clin. Obstet. Gynec.* 9 (1966) 472
- [5] WAGNER, K., E. SALING: Ergebnisse der Umfrageaktion über die Versorgung des Kindes in der Perinatalperiode in der BRD und West-Berlin 1971. In: DUDENHAUSEN, J. W., E. SALING: *Perinatale Medizin Band IV.* Thieme, Stuttgart 1973

Prof. Dr. E. Saling  
Unit of Perinatal Medicine  
Mariendorfer Weg 28—38  
D-1000 Berlin 44/Germany