

Original articles

J. Perinat. Med.
7 (1979) 3

Fetal heart rate during a maternal grand mal epileptic seizure

K. Teramo, V. Hiilesmaa, A. Bardy, S. Saarikoski

Depts. I and II of Obstetrics and Gynecology, University of Helsinki, Finland

An increased rate of malformations, particularly oral clefts, of newborn infants born to epileptic mothers has been reported in several studies [1, 2, 3, 4, 7]. Although maternal ingestion of antiepileptic drugs is strongly suspected of causing congenital defects, the effect of epilepsy itself or a combined effect of drug intake and epilepsy have not been excluded as etiological factors. Very little is known about fetal oxygenation during a maternal grand mal seizure. We describe here two cases in which fetal heart rate (FHR) was recorded during a maternal epileptic seizure during the first stage of labor.

1.1 Case no. 1.

The patient was a 28-year old primipara whose own birth weight had been 1600 g. A small cleft palate was closed operatively when she was 2 years of age. She had three grand mal seizures since the age of 25. The last seizure occurred 9 months before the onset of her pregnancy. Her medication was diphenylhydantoin 100 mg daily before the pregnancy. The same dose was continued unchanged during the pregnancy. The patient attended an outpatient clinic for pregnant epileptics regularly during her pregnancy, which progressed uneventfully until term. Serial determination of 24-hour urinary excretion of estriol and human placental lactogen of the maternal serum gave normal values during the last weeks of pregnancy. FHR showed normal patterns during weekly cardiotocographic recordings during the last month of pregnancy. Labor started spontaneously at term. The membranes were ruptured and a spiral electrode was attached to the fetal scalp for recording of FHR when the cervix was 4 cm dilated 4.5 hours before delivery. 43 minutes before delivery when the cervix was 6 cm dilated the patient unexpectedly suffered a grand mal epileptic seizure, which lasted 2.5 minutes (Fig. 1). Immediately after the seizure the patient became cyanotic for a few minutes. 2 minutes after the beginning of the seizure the patient received diazepam 10 mg intravenously

Curriculum vitae

KARI TERAMO was born in 1938 and obtained his medical degree in 1965 at the University of Helsinki Medical School. He completed 4 years of residency at the Department of Obstetrics and Gynecology, University Central Hospital of Helsinki. He was a research fellow at the Cardiovascular Research Institute, University of California, San Francisco, for 2 years from 1971 to 1973. Since 1974 he is a perinatologist at the Department of Obstetrics and Gynecology, University of Helsinki, Finland.



and 10 mg intramuscularly. Fig. 1 shows FHR before, during and after the grand mal seizure of the mother. FHR decelerated below 120 beats/min for over 13 minutes. The short-term variability of FHR decreased during the deceleration period, after which there was a phase of tachycardia up to 165 beats/min with decreased short-term and long-term variability. The mother's blood pressure was normal during the fetal bradycardia. 29 minutes after the beginning of the seizure a late deceleration bradycardia wave is seen. The fetus was delivered by cesarean section 43 minutes after the beginning of the seizure. The cesarean section was performed under general anesthesia with nitrous oxide/oxygen and succinyl choline infusion after induction with thiobarbitone. The male infant weighed 3630 g and received an APGAR score of 8 at the age of one minute. The condition of the newborn infant was good during the following days except for slightly reduced muscular tone. The mother recovered from the operation uneventfully. At delivery the concentration of diphenylhydantoin in maternal venous blood was only 0.9 $\mu\text{g/ml}$. The patient assured having taken her medication regularly. The mother and the infant were discharged in good condition 9 days after the delivery.

0300-5577/79/0007-0003\$02.00

© by Walter de Gruyter & Co. · Berlin · New York

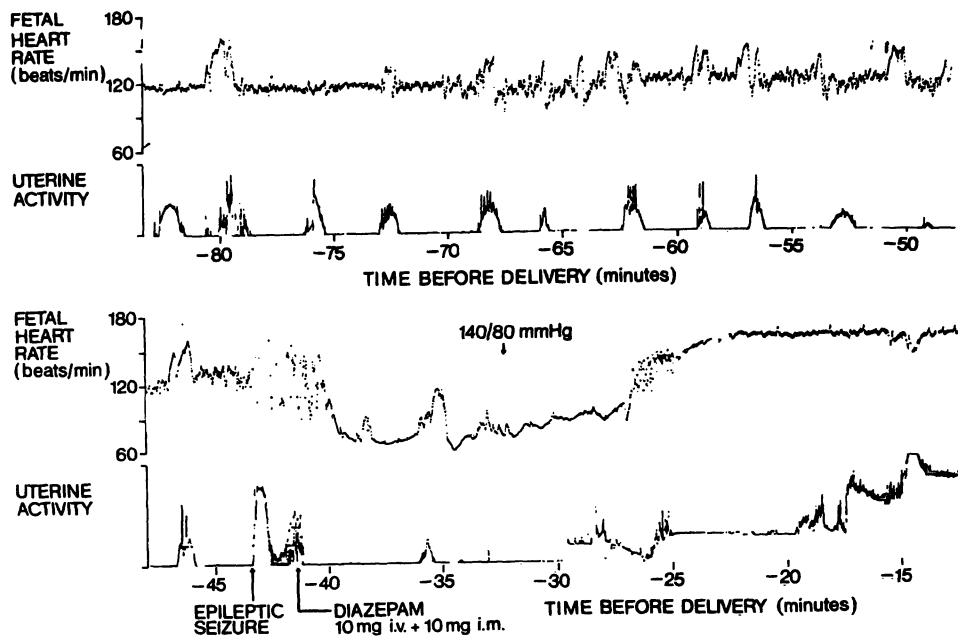


Fig. 1. Fetal heart rate recorded via a scalp electrode and uterine activity before, during and after a maternal epileptic grand mal seizure during the first stage of labor. The gestation was 280 days.

1.2 Case no. 2.

The patient was a 24-year old primipara who had grand mal epileptic seizures 1 to 2 times a year during the last 9 years. Her medication was diphenylhydantoin 150 mg twice daily. The patient had no epileptic seizures during her pregnancy before she was admitted to hospital 12 days post term. She was treated during her pregnancy for urinary tract infection for several months alternately with sulphon amides and nitrofurantoin. She was admitted to the hospital 12 days past her estimated date because of irregular uterine contractions. She received diazepam 10 mg and pethidine 75 mg intramuscularly 32 hours before delivery and pethidine 75 mg intramuscularly 18 hours before delivery. 13 hours before delivery she received diphenylhydantoin 150 mg orally. 8 hours before delivery an oxytocin infusion was started because of weak uterine activity. Regular uterine contractions started 30 minutes from the beginning of the oxytocin infusion. The membranes were ruptured when the cervix was dilated 4 cm 2 hours 53 minutes before delivery, and a spiral electrode was attached to the fetal scalp to record FHR. 87 minutes before delivery the patient suddenly suffered from a typical grand mal epileptic seizure and fell from the bed onto the floor. The patient did not hurt herself, and after she was lifted back onto her bed, the fetal electrode was reconnected to the recording apparatus. There was a 90-second lag in the recording of FHR (Fig. 2). After the FHR recording was reconnected, a deceleration to 100 beats/min was observed (Fig. 2). It is not certain whether this was an early or a late deceleration, but there was an increase in FHR up to 165 beats/min and at the same time the short-term and long-term variability of FHR decreased. During the following uterine contractions no decelerations in FHR were noted. The maternal hyperventilation after the seizure is clearly

seen on the external recording of uterine activity. The maternal hyperventilation stopped promptly after 5 mg of diazepam was given intravenously. Because the mother was restless and disorientated after the epileptic seizure, the fetus was delivered by cesarean section under general anesthesia. The mother received 5 mg of diazepam intravenously twice 8 and 13 minutes before the delivery. Despite this, a vigorous healthy male infant weighing 4140 g was born. He received an APGAR score of 10 at the age of one minute and was discharged in good condition with his mother at the age of 6 days. Determinations for diphenylhydantoin concentrations in the maternal blood was not performed.

2 Discussion

A grand mal epileptic seizure causes marked acute cardiovascular changes both in humans [5] and in experimental animals [6, 8]. In the brain the blood flow increases considerably during an epileptic seizure [6] but very little is known about the placental blood flow during maternal seizures. Case no. 1 demonstrates clearly that a grand mal epileptic seizure of the mother can lead to transient fetal asphyxia. Whether this is produced by a decreased placental blood flow during the maternal seizure or is secondary to the postictal apnea of the mother is not evident. In case no. 2 FHR changes were less marked after the maternal grand mal seizure than in case no. 1, but the tachycardia

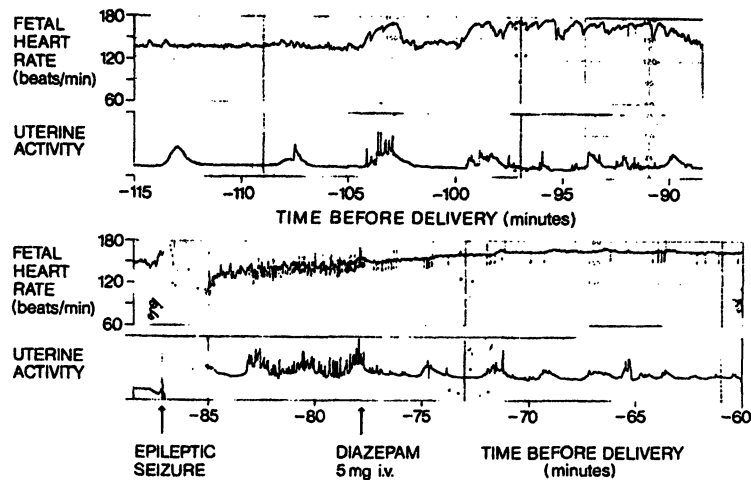


Fig. 2. Fetal heart rate recorded via a scalp electrode and uterine activity before and after a maternal epileptic grand mal seizure during the first stage of labor. The gestation was 292 days. There was a 90-second lag in the recording from the beginning of the epileptic seizure because the mother fell from the bed onto the floor.

phase resembles the tachycardia seen in the first fetus and probably represents recovery from an acute phase of asphyxia. Both infants were vigorous at birth, which shows that the fetuses recovered rapidly in utero from the transient asphyxia. These

two cases demonstrate that a maternal grand mal epileptic seizure can be ominous to the fetus. It is therefore important that epileptic seizures are controlled by optimal medication throughout pregnancy.

Summary

Although maternal ingestion of antiepileptic drugs is strongly suspected of causing congenital defects, particularly oral clefts, the effect of epilepsy itself or a combined effect of drug intake and epilepsy have not been excluded as etiological factors. Very little is known about fetal oxygenation during a maternal grand mal epileptic seizure.

We describe two cases in which fetal heart rate was recorded during a maternal epileptic seizure during labor. The first fetus became clearly asphyctic as judged from the fetal heart rate recording: immediately after the epileptic seizure there was a 13-minute continuous

bradycardia wave with decreased short-term variability. After the bradycardia a phase of tachycardia with decreased short-term and long-term variability occurred. In the other fetus there was only a short period of bradycardia, which was followed by a phase of tachycardia and decreased short-term and long-term variability. Both fetuses were vigorous at birth 43 and 87 minutes, respectively, after the epileptic seizures of their mothers. We conclude that a maternal grand mal epileptic seizure can be ominous to the fetus. It is therefore important that epileptic seizures are controlled by optimal medication throughout pregnancy.

Keywords: Fetal asphyxia, fetal heart rate, grand mal epileptic seizure, pregnancy.

Zusammenfassung

Fetale Herzfrequenz während eines mütterlichen epileptischen Anfalls (Grand mal)

Durch die Einnahme von Anti-Epileptika werden höchstwahrscheinlich angeborene Mißbildungen, insbesondere Mundspalten verursacht. Jedoch konnten die Epilepsie selbst sowie das Zusammenwirken von Antiepileptika-Einnahme und Epilepsie als ätiologische Faktoren nicht ausgeschlossen werden. Bisher ist sehr wenig über die Fetale Sauerstoffversorgung während eines Grand mal's bekannt.

Es werden 2 Fälle beschrieben, bei denen die Mutter während der Wehen einen epileptischen Anfall hatte, währenddessen die fetale Herzfrequenz aufgezeichnet wurde. Der erste Fetus hatte eine Asphyxie, wie sich eindeutig aus dem Herzfrequenzmuster ableiten ließ: sofort mit dem Anfall setzte eine 13-minütige Bradykardie mit abnehmenden Kurzzeitschwankungen ein. Nach der Bradykardie folgte eine Tachykardie-Phase mit abnehmenden schnellen und langsamen Oszillationen. Im zweiten Fall ereignete sich bei dem Fetus nur eine kurze Bradykardie-Phase, wiederum

gefolgt von abnehmenden Kurzzeit- und Langzeitschwankungen. Beide Kinder wurden nach 43 bzw. 87 Minuten, also jeweils nach dem mütterlichen epileptischen Anfall, gesund geboren. Wir schließen aus unseren Beobachtungen,

daß sich ein epileptischer Anfall bedrohlich auf den Feten auswirken kann. Während der gesamten Schwangerschaft ist deshalb eine optimale Medikation zwecks Kontrollierung der epileptischen Anfälle von großer Wichtigkeit.

Schlüsselwörter: Epileptischer Anfall, fetale Asphyxie, fetale Herzfrequenz, Schwangerschaft.

Résumé

Fréquence cardiaque foetale durant une attaque épileptique de grand mal chez la mère

Bien que l'absorption maternelle de drogues antiépileptiques soit fortement soupçonnée de provoquer des déficiences congénitales, particulièrement des fissures orales, il n'est pas exclu que l'effet de l'épilepsie elle-même ou un effet combiné d'absorption de drogue et d'épilepsie agissent comme des facteurs étiologiques. On sait encore très peu de choses sur l'oxygénation pendant une attaque épileptique de grand mal chez la mère.

Le présent article traite de deux cas où la FCF a été enregistrée pendant une attaque épileptique maternelle en cours de travail. Le premier foetus est devenu nettement asphyxique ainsi qu'on a pu en juger d'après l'enregistrement de la FCF: immédiatement après l'attaque

d'épilepsie on a pu observer une bradycardie continue de 13 min. avec variabilité décroissante à court terme. La bradycardie fut suivie d'une phase de tachycardie avec variabilité décroissante à court terme et à long terme. Chez l'autre foetus on n'a relevé qu'une période brève de bradycardie, suivie d'une phase de tachycardie et de variabilité décroissante à court terme et à long terme. Les deux foetus étaient vigoureux à la naissance, respectivement 43 et 87 minutes après les attaques épileptiques de leur mère. Nous en avons déduit qu'une attaque épileptique de grand mal chez la mère peut avoir des conséquences malfaisantes pour le foetus, d'où l'importance du contrôle des attaques d'épilepsie par médication optimale tout au long de la grossesse.

Mots-clés: Asphyxie foetale, attaque épileptique de grand mal, fréquence cardiaque foetale (FCF), grossesse.

Bibliography

- [1] BJERKEDAL, T., S. L. BAHNA: The course and outcome of pregnancy in women with epilepsy. *Acta Obstet. Gynecol. Scand.* 52 (1973) 245
- [2] FEDRICK, J.: Epilepsy and pregnancy: A report from the Oxford Record Linkage Study. *Brit. med. J.* 2 (1973) 442
- [3] KNIGHT, A. H., E. G. RHIND: Epilepsy and pregnancies in 59 patients. *Epilepsia* 16 (1975) 99
- [4] LOWE, C. R.: Congenital malformations among infants born to epileptic women. *Lancet* I (1973) 9
- [5] MEYER, J. S., F. GOTOH: Cerebral metabolism during epileptic seizures in man. *Trans. Amer. Neurol. Ass.* 90 (1965) 23
- [6] PLUM, F., J. B. POSNER, B. TROY: Cerebral metabolic and circulatory responses to induced convulsions in animals. *Arch. Neurol.* 18 (1968) 1
- [7] SPEIDEL, B. D., S. R. MEADOW: Maternal epilepsy and abnormalities of the fetus and newborn. *Lancet* II (1972) 839
- [8] TERAMO, K., N. BENOWITZ, M. A. HEYMANN, K. KAHANPÄÄ, A. SIIMES, A. M. RUDOLPH: Effects of lidocaine on heart rate, blood pressure, and electrocorticogram in fetal sheep. *Amer. J. Obstet. Gynecol.* 118 (1974) 935

Received October 22, 1977. Accepted February 3, 1978.

Kari Teramo, M.D.
Dept. Obstet. Gynec.
University of Helsinki
SF-00290 Helsinki
Finland